



Glaucoma in 2021: A Whole New Ballgame

New meds and MIGS brighten the prospects for longtime sufferers of this disease, an expert explained.

For years, glaucoma treatment was limited to just a few drops and, for more dire cases, invasive surgical techniques. Fast forward to 2021 and optometrists have a wealth of new options to treat patients, from medications that offer superior IOP lowering in just one bottle to a constellation of minimally invasive glaucoma surgery (MIGS) techniques that divert fluid from the anterior chamber with low risk to patients.

“Glaucoma has no cure, but if you can lower the eye pressure, the condition can be stabilized. Lowering IOP is all we’ve got, and we need to use all the tools in our toolbox to get there,” said Arkadiy Yadgarov, MD, during his Wednesday session, “Glaucoma 2021, the Latest in Glaucoma Management.”

One new glaucoma medication is Vyzulta (Bausch + Lomb), which Dr. Yadgarov described as “pretty much latanoprost on steroids.” Vyzulta is latanoprost plus nitric oxide, the latter of which stimulates flow through the trabecular outflow. Although it has the same side effect profile as latanoprost, it offers an average 1.2mm Hg greater IOP-lowering ability. Dr. Yadgarov suggested considering Vyzulta in a situation where a patient is on a prostaglandin analog but their pressure should be 1mm Hg to 3mm Hg lower to achieve a more ideal IOP.

Another newer drop is Rhopressa (Aerie Pharmaceuticals), a rho-kinase inhibitor that offers a new mechanism of action and is the first med to directly work at the location that’s the catalyst for IOP elevation.

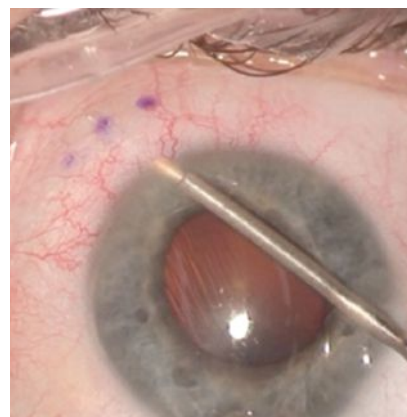

Photo: Justin Schweizer, OD

The Xen gel stent creates a drainage pathway from the anterior chamber to the subconjunctival space to lower IOP.

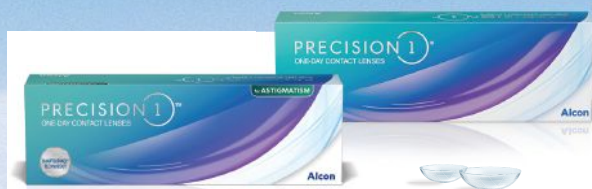Rhopressa relaxes the trabecular meshwork to improve aqueous outflow. It tends to work better on IOPs that are under 23mm Hg, Dr. Yadgarov explained.

A third recent addition to the medication paradigm is Rocklatan (Aerie Pharmaceuticals), a combination of Rhopressa and latanoprost, which Dr. Yadgarov explained offers superior IOP lowering in only one bottle.

“Rocklatan is the most powerful medication for glaucoma on the market,” Dr. Yadgarov asserted in his talk, noting that one-third of patients on this therapy will achieve greater than 40% IOP reduction; furthermore, the regimen also provides the additional benefit of having no systemic side effects. Still, there is a high incidence of hyperemia, he noted, with 30% to 50% of patients developing significant presentations.

See **GLAUCOMA**, Page 13

PRECISION1® FOR ASTIGMATISM READY TO PRESCRIBE



Born from the Water Gradient Technology of DAILIES TOTAL1®

- Featuring the proven **PRECISION BALANCE 8|4®** lens design
- **99%** first-lens fit success rate^{1*}
- **Easy** to handle

All at a mainstream price.

Fit your patients in PRECISION1® for Astigmatism.

Alcon

*Based on lens movement, centration and rotation at initial fitting.
 Reference: 1. In a study where n=78 eyes; Alcon data on file, 2020.

See product instructions for complete wear, care and safety information. © 2020 Alcon Inc. 11/20 US-PRA-2000031



Glaucoma in 2021: A Whole New Ballgame

New meds and MIGS brighten the prospects for longtime sufferers of this disease, an expert explained.

For years, glaucoma treatment was limited to just a few drops and, for more dire cases, invasive surgical techniques. Fast forward to 2021 and optometrists have a wealth of new options to treat patients, from medications that offer superior IOP lowering in just one bottle to a constellation of minimally invasive glaucoma surgery (MIGS) techniques that divert fluid from the anterior chamber with low risk to patients.

“Glaucoma has no cure, but if you can lower the eye pressure, the condition can be stabilized. Lowering IOP is all we’ve got, and we need to use all the tools in our toolbox to get there,” said Arkadiy Yadgarov, MD, during his Wednesday session, “Glaucoma 2021, the Latest in Glaucoma Management.”

One new glaucoma medication is Vyzulta (Bausch + Lomb), which Dr. Yadgarov described as “pretty much latanoprost on steroids.” Vyzulta is latanoprost plus nitric oxide, the latter of which stimulates flow through the trabecular outflow. Although it has the same side effect profile as latanoprost, it offers an average 1.2mm Hg greater IOP-lowering ability. Dr. Yadgarov suggested considering Vyzulta in a situation where a patient is on a prostaglandin analog but their pressure should be 1mm Hg to 3mm Hg lower to achieve a more ideal IOP.

Another newer drop is Rhopressa (Aerie Pharmaceuticals), a rho-kinase inhibitor that offers a new mechanism of action and is the first med to directly work at the location that’s the catalyst for IOP elevation.

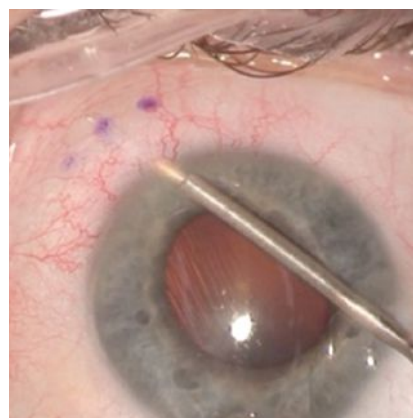

Photo: Justin Schweizer, OD

The Xen gel stent creates a drainage pathway from the anterior chamber to the subconjunctival space to lower IOP.

Rhopressa relaxes the trabecular meshwork to improve aqueous outflow. It tends to work better on IOPs that are under 23mm Hg, Dr. Yadgarov explained.

A third recent addition to the medication paradigm is Rocklatan (Aerie Pharmaceuticals), a combination of Rhopressa and latanoprost, which Dr. Yadgarov explained offers superior IOP lowering in only one bottle.

“Rocklatan is the most powerful medication for glaucoma on the market,” Dr. Yadgarov asserted in his talk, noting that one-third of patients on this therapy will achieve greater than 40% IOP reduction; furthermore, the regimen also provides the additional benefit of having no systemic side effects. Still, there is a high incidence of hyperemia, he noted, with 30% to 50% of patients developing significant presentations.

See **GLAUCOMA**, Page 13

WHAT'S INSIDE

- Keep up with the latest systemic meds..... 3
- Be prepared to handle ocular trauma 4
- Don't succumb to the pressure in glaucoma..... 5
- Handle tough cases calmly..... 5
- Sclerals make a difference 6
- Exhibit hall info..... 8
- Today's courses..... 10
- Consider the benefits of controversy 12
- CEE TQ Courses..... 13
- Ocular consequences of obstructive sleep apnea..... 14

Going Viral: Managing Herpetic Eye Disease

Session with great audience involvement provided practical tips.

Many attendees were willing to participate in the questions asked by Nate Lighthizer, OD, an associate professor at Oklahoma College of Optometry, during yesterday's lecture, “Going Viral: HSV, HZO, EKC.” As he reviewed three different cases of viral disease, Dr. Lighthizer polled the attending audience to see how they would approach the case or follow through with treatment. It was an engaging session that helped optometrists become more confident in handling these challenging conditions.

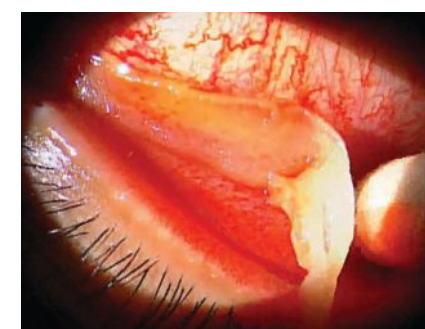According to Dr. Lighthizer, viral eye disease can present in many different ways depending on the condition. Dr. Lighthizer ensured that attendees would walk away more familiar with the risk factors for developing each condition its most common ocular symptoms and signs and review ocular treatments

depending on the variety the clinician faces.

The MO on HZO

Dr. Lighthizer first presented a case involving a 74-year-old Cherokee woman who had unilateral red eye, headache and an irregular pattern on her cornea. After polling the nearly 150 ODs attending the lecture, the differential breakdown was between herpes simplex and herpes zoster. Dr. Lighthizer passed on advice he previously received: “Any time you see unilateral red eye, herpes simplex should be on your differential.”

Cleverly enough, this wasn't the case with this patient. A live audience member pointed out the importance of taking into consideration the patient's age. Despite the absence of rash on the patient's forehead, Dr. Lighthizer pointed out that herpes zoster ophthalmicus



This pseudomembrane in the left lower fornix of an EKC patient is being peeled with a cotton tip applicator.

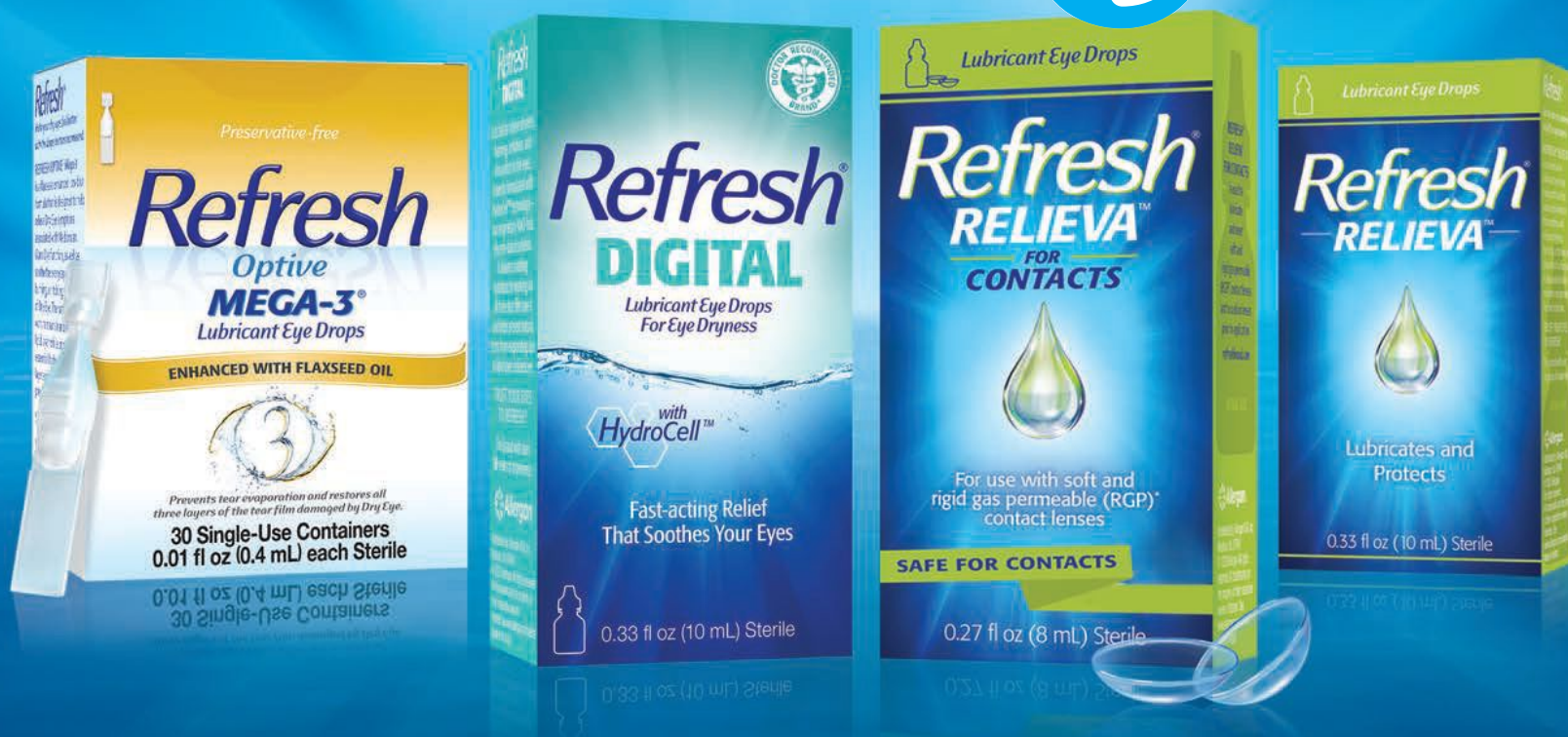can sometimes present in the globe before the forehead in a small percentage of patients. He also noted the appearance of a pseudodendrite. “Look for elevation and ulceration,” he mentioned. Making this differential would reveal whether to use a steroid or use an oral antiviral in the case of a dendrite.

See **GOING VIRAL**, Page 14

OPEN YOUR EYES TO

Refresh[®]

CONCIERGE



DISCOVER EXCLUSIVE ACCESS TO ALL THINGS REFRESH[®].

Our full-service, dedicated team is here to assist you and your staff with all your REFRESH[®] needs.



REFRESH[®]
SAMPLES



PATIENT
COUPONS



PRODUCT
EDUCATION



REFRESH[®] DIRECT
ECOMMERCE

Call us and see how REFRESH[®] Concierge can help you bring relief to your patients.

833-REF-SMPL 7:30 a.m.–7 p.m. CT, M–F

Today: 11:00am–12:00pm ROOM A313/314

Monitoring Medications: What to Watch For

It's important to be aware of potential ocular side effects systemic drugs can inflict on your patients.

Keeping up with the latest systemic medications available today can be overwhelming, along with the growing list of ocular side effects to each medication. While not all patients experience side effects, it's important to know what they are, what symptoms they can potentially cause and how to monitor them appropriately. In this morning's lecture, Nate Lighthizer, OD, will cover a wide variety of medications that not only he and optometrists in general prescribe, but also those prescribed by primary care physicians, internists and other medical doctors.

"Even though we're not prescribing them, we need to be aware of what the potential ocular side effects are—no matter how rare that may be," says Dr. Lighthizer.

Medications that can cause toxicity will be discussed, such as corticosteroids and many different medication classes, including tetracyclines, antiepilepsy drugs and antiarrhythmics. Given the widely recognized associations with eye care, he'll give particular emphasis to the effects of Flomax, Viagra and Plaquenil (hydroxychloroquine), the latter of which Dr. Lighthizer says he especially watches out for.

"The first case we will cover is an example of Plaquenil toxicity, where a 67-year-old female came in to the office with no visual complaints and yet she's visual field showing defects and has changes in the back of the eye," he says. "The important thing to note with a lot of these medications—especially Plaquenil—is that early detection is critical, even before the patient notices vision changes. We can detect these changes with OCTs, visual fields and ERGs among other testing. By doing this and following these patients appropriately, we can detect changes before they even notice, and oftentimes these medications can be stopped while working through the PCP and we can save a patient's potential visual loss."

To help in monitoring patients using Viagra, Dr. Lighthizer will discuss side effects such as blurred vision, flashing lights and mild color vision defects; for patients taking Flomax, he'll discuss the potential side effects that can result in significant problems during cataract surgery. Topamax also presents concerning side effects, including uveal effusion syndrome, which is associated with serous retinal detachment.

Dr. Lighthizer says while some of the cases to be discussed are more rare than others, attendees

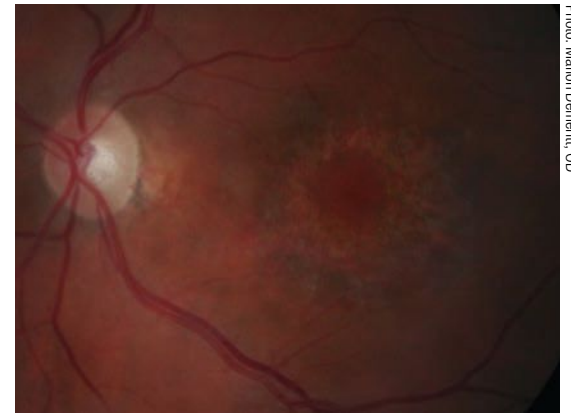


Photo: Marion Demeritt, OD

The classic parafoveal ring-shaped "bull's eye" RPE defect characteristic of Plaquenil toxicity.

leaving the lecture will understand the importance of having these systemic medications in the back of their minds and ways in which they can cause unintended ocular side effects. That will lay the groundwork for conversations with your patients asking specific questions on their social habits and any Rx meds and OTC supplements they take, so that you can empower them to decrease the risk of any drug reactions or interactions. ■

SPEAKER SPOTLIGHT



Dr. Melton's SECO 2021 course schedule includes:

Special Session:
Clinical Perspectives in Patient Care

Today
8:00am–10:00am

Amphitheater A2

Ron Melton, OD

Dr. N. Ron Melton is an optometrist from Charlotte, NC, who specializes in comprehensive eye exams and contact lenses. His special interests include ocular disease/glaucoma as well as anterior segment conditions. He received his undergraduate degree from Greensboro College and his Doctor of Optometry degree from the Pennsylvania College of Optometry. He also served as a captain in the US Army as a clinical optometrist at Hawley Army Hospital. He is an adjunct faculty member of the Indiana University School of Optometry and the Pennsylvania College of Optometry. He is a member of the American Academy of Optometry, the American Optometric Association, the North Carolina Optometric Association, the Optometric Glaucoma Society and the Piedmont Optometric Society.

SPEAKER SPOTLIGHT



Dr. Thomas's SECO 2021 course schedule includes:

Special Session:
Clinical Perspectives in Patient Care

Today
8:00am–10:00am

Amphitheater A2

Randall Thomas, OD

Dr. Thomas, a 1981 graduate of the Pennsylvania College of Optometry, is in full-time clinical practice in Concord, NC. He was named the "Glaucoma Educator of the Year" by the American Academy of Optometry in 1997. He and Dr. Melton co-author *Review of Optometry's* annual guide to clinical care, now in its 25th year. He is on the professional staff at Carolinas Medical Center-Northeast and the teaching faculty of the Cabarrus Family Medicine Residency Program. Dr. Thomas has served as a consultant to the American Optometric Association on its Council on Clinical Optometric Care and Hospital Privileges Committees. He has served as an ophthalmic drug principal investigator for the FDA. Dr. Thomas has lectured worldwide with Dr. Melton on the diagnosis and treatment of eye diseases.

Today: 2:15pm–4:15pm ROOM A411/412

Ocular Trauma: How to be a First-Responder

Steel your nerves as you prepare for this afternoon's two-hour lecture on trauma cases. Michelle Welch, OD, staff optometrist for the Idabel Choctaw Nation Health Clinic and professor at the Northeastern State University Oklahoma College of Optometry, will discuss patients who were cared for by her and NSU students and faculty in the hospital emergency room.

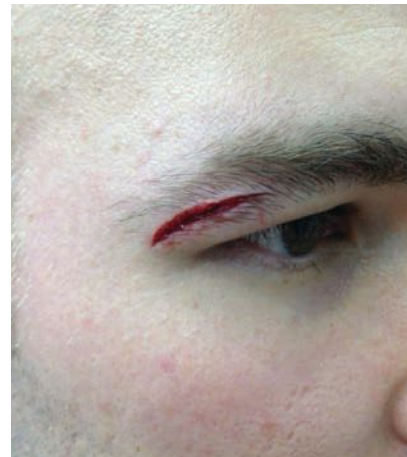"Although trauma isn't something that a practice may encounter every day, it is important to be ready with equipment and knowledge to manage any trauma patient that may arrive in our office," Dr. Welch acknowledges.

The session will discuss management of the various presentations of trauma in detail, including minor surgical techniques that can be performed in-office, medications necessary for treatment and indications for referral to secondary care after stabilizing the patient.

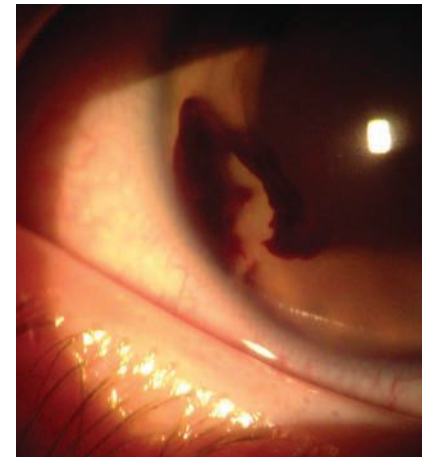Offering such services is integral to the image of optometry. "We want our patients to think of us as their primary eyecare provider," she notes. "With anything that affects

Lacerations that Should be Referred

- Associated with ruptured globe
- Involve lacrimal drainage system
- Involve levator or superior rectus
- Associated with intraocular foreign body
- Associated with extensive tissue loss > 1/3 of lid or severe distortion of anatomy
- If discomfort is severe (e.g., deep laceration involving lid margin that will require a two-layer closure technique)



Consider risk of tetanus in all laceration patients.



Be sure to rule out a ruptured globe in hyphema cases.

their eyes, the area around their eyes or their vision, they should be comfortable coming to us for help."

Cases discussed include eyelid laceration stabilization, foreign bodies, chemical burns, globe lacerations, blow-out fractures and hyphema. Dr. Welch will guide the attendees through an assessment of extent of injury and provide tips to determine if the injury can be fixed in the optometric office or needs higher-level referral. "The important thing to keep in mind is making sure that we

do the right thing for each patient based on the clinical findings of a thorough and comprehensive exam in a timely manner with trauma cases," Dr. Welch says. "Be efficient in order to identify cases that need referral for care outside the optometric scope of practice and transfer the patient to appropriate care effectively when needed."

Dr. Welch believes excellent staff training is important to have in place when caring for trauma patients. "They need to know how to

triage trauma cases appropriately, ensuring that patients are seen in a timely manner," she suggests. Staff need to know appropriate questions for taking case history—asking about how and when the trauma occurred, along with other details, including when the patient's last tetanus shot was and any medication allergies.

"Come ready for a spirited review of trauma cases—no other preparation is necessary," Dr. Welch says. ■

THE VIEW

LUXURY EYEWEAR

VIEW What is Next for 2021!
The View is the place to be at SECO if you make or influence eyewear buying decisions. Learn what's new and what's next and how to solve even your most difficult fitting challenges. Mix and mingle with your peers who face the same issues you do. Share ideas and strategies for creating the most dynamic inventory mix for your unique environment while increasing patient satisfaction and practice revenue.

In The VIEW Presentations
Frame Fashion Trends Impacting Optometry Sales!
NOT FOR CE CREDIT, NO REGISTRATION NECESSARY

Frame Fashion Tour
Laurie O'Keefe Pierce
Friday, April 30th, 4:30 PM – 5:00 PM
Saturday, May 1st, 11:30 AM – 12:00 PM

Sell \$1000 Frames on a Daily Basis
Andy Tabrizipour
Friday, April 30th, 10:30 AM - 11:00AM

Movie & Cinema Influencing Fashion & Style
Gazal Tabrizipour
Saturday, May 1st, 1:30 PM - 2:15 PM

CO-LOCATED MEETINGS

SECO 2021 is excited to host affiliate and associated organizations during this year's annual meeting. A continued build of the profession's most valuable education offering, SECO 2021 provides a synergy of more learning and more variety in one meeting place!



AFOS



AACO
American Association of Corporate Optometrists



COLLEGE OF OPTOMETRISTS IN VISION DEVELOPMENT
PREVENTION • ENHANCEMENT • REHABILITATION



Scleral LENS EDUCATION SOCIETY

Saturday: 8am–10am AMPHITHEATER A2

Take a Deep Dive into Glaucoma

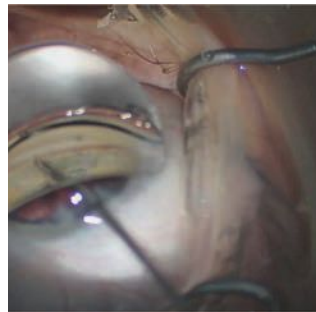This course will offer insight into common and controversial knowledge associated with the disease.

Saturday morning's special session, "Anterior Segment Advances: the Future is Now," will take a look at the latest and greatest in this important subset of ocular care. The presenters, John Berdahl, MD, and Lawrence Woodard, MD, hope attendees will walk away from the course with a more solid understanding of the factors that play a role in the development and progression of glaucoma and how to manage them, the pathophysiology of glaucoma, the different ways to treat glaucoma and the OD-MD comanagement relationship.

It is a common belief that glaucoma is a one-pressure disease; in actuality, it may be comprised of both intraocular pressure and intracranial pressure, the presenters will explain. Drs. Berdahl and Woodard define glaucoma as an optic neuropathy that causes optic nerve damage/cupping and characteristic visual field loss.

According to the Ocular Hypertension Treatment Study, lowering IOP in cases of ocular hypertension reduces the risk of progression to glaucoma almost by half, from 9.4% to 4.9%. The study found five independent risk factors for the disease: age, intraocular pressure, vertical cup-disc ratio, visual fields and pachymetry.

The doctor duo will address the argument that translaminal pressure also plays a significant role in glaucoma. Using evidence-based literature, they will note that cerebrospinal fluid pressure is decreased in glaucomatous eyes and that translaminal pressure differences strongly



The iStent inject (Glaukos) is indicated for use in combination with cataract surgery for the reduction of intraocular pressure in cases of mild to moderate primary open-angle glaucoma.

correlate with visual field loss.

With this new-found knowledge in mind, Drs. Berdahl and Woodard plan to reexamine the role of intracranial pressure and cerebrospinal fluid in glaucoma and draw conclusions between the two and other established factors of the disease.

The pair will also incorporate a discussion on minimally invasive glaucoma surgeries and presbyopia-correction intraocular lenses into the course, including which devices are available, when to choose which and how to manage each. To improve post-op outcomes, options include femtosecond laser-assisted cataract surgery, intraop-

erative aberrometry, digital image guidance, automated capsulotomy, swept-source OCT biometry and new drug delivery options. All will be reviewed in the lecture.

To create a seamless patient experience and encourage optimal ocular outcomes, an effective, efficient OD-MD relationship needs to be present at the outset. The foundation should ideally revolve around clear patient and doctor expectations, open communication between all parties and continued appropriate care.

"A new and better fundamental understanding of disease like glaucoma will shape new therapeutic and diagnostic advances," Dr. Berdahl says. "Technology is changing how we practice today, and it will only continue to do so." He urges all attendees to get involved with technological advancements to push the field forward and satisfy any unmet needs patients may have. ■

Trust the Process: How to Handle Tough Cases Calmly

Attendees of Wednesday's "Medical and Surgical Grand Rounds" talk may have been a little confused when Brooks Alldredge, OD, of the Pacific Cataract and Laser Institute, disclosed to the crowd his bone to pick with the very concept. Grand rounds to him often meant presenting rare and complex problems that the lecturer had diagnosed and managed successfully with near effortless skill and confidence.

"Not has only that experience been contrary to my clinical experience, but it can send a message that uncertainty, doubt and even error are signs that somebody more competent knows how to take care of patients better than you or me do," Dr. Alldredge noted in his talk. "Taking responsibility for people's health is inherently uncertain, so how do we make effective decisions given that uncertainty?"

According to Dr. Alldredge, learning from cases is far better than learning from concepts, and so he decided to tell the story of one patient with a complex neuro-ophthalmic condition that proved to be vision- and life-threatening. In describing the diagnosis and treatment in detail, Dr. Alldredge reviewed his thought process behind each test, decision, discussion, action and result in the order they occurred. Warts and all, he divulged what embarrassed him in his handling of the case and how he was able to now provide strategies for clinical decision-making, plus a guide for presenting bad news.

Dr. Alldredge is a strong believer in optometrists developing their own disciplined process to fall back to and avoid inaction or treading water in the face of making critical decisions. He starts with coming up with possible broad pathophysiological

processes that could be responsible for his patient's history, eliminate any unlikely ones and determine what findings to examine. After new findings emerge, Dr. Alldredge reiterates his process, this time narrowing down the pathophysiology that can explain the history and presentation.

He related to the audience, "There is one thing that we'd have to do with every patient we see and we can't get out of it: make a decision."

To avoid feeling immobilized by a difficult case, Dr. Alldredge changed his way of thinking from considering his diagnosis a reflection on his competency as a doctor to viewing it as just the best guess that he can make at that moment. "You have to stick your neck out, make the best stab you can going forward and see what happens," he says.

To combat the cognitive traps to clinical thinking, Dr. Alldredge

provided three strategies to reduce these errors; namely, communication, compassion and critical reasoning.

By going through the questions that he typically asks himself when handling complex cases, Dr. Alldredge presented his disciplined approach that helped him when things get hard. He hopes it will help other optometrists move forward and not freeze at the first possibility of being stumped. ■

Dr. Alldredge's Strategy for Delivering Bad News

S: Set up the discussion

P: Understand patient's perception

I: Obtain the patient's invitation

K: Provide knowledge

E: Address emotions with empathy

S: Strategize and summarize

Preparing For the Scleral Surge

As this modality grows in popularity, it's worth making sure you're up-to-date on all it has to offer.

Scleral lenses are “revolutionizing the way we practice,” according to Jason Jedlicka, OD. At his session yesterday morning, “Scleral Lens Complications and Controversies,” he presented several key questions to guide his discussion of this contact lens modality and its rapidly evolving role. He used several case examples to illustrate concerns with increasing use, challenges/frustrations that come with scleral lens fitting and areas of controversy.

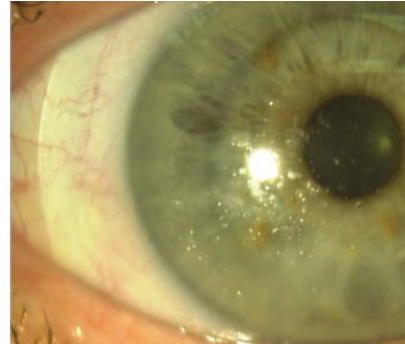
Dr. Jedlicka categorized scleral complications into anterior lens surface non-wetting, conjunctival hypertrophy/prolapse, hypoxia, peripheral corneal bullae, posterior lens fluid reservoir fogging and suctioned fits that cause IOP elevation and wound gaping. He noted that reducing the risk of hypoxia specifically involves carefully considering lens thickness, using the highest Dk materials, fitting with the lowest reasonable vault and monitoring high-risk eyes closely.

Scleral lenses help treat ocular surface symptoms and corneal disease, but they increase the exposed surface area of the ocular surface and are dryer, increasing the risk of visual issues and creating more lid friction. Management of chronic surface issues includes treating the problem with lid hygiene, omega-3s and/or meds, and stabilizing the tear film through dry eye management efforts. This may require a customized care regimen that includes alcohol-based cleaner, Progent treatments to remove protein build-up and H₂O₂ or gas permeable case systems.

When managing acute ocular surface issues, Dr. Jedlicka advocated for plasma-treated lenses and Hydra-PEG (Tangible Science) if there is concern or history of non-wetting. If the scleral lenses are shipped dry, he recommended cleaning and soaking them prior to dispensing. He noted that adding conditioner or lubricant eye drops to the lens applicator at the time of insertion may help with initial non-wetting issues.

Scleral lens patients dealing with ocular surface issues should be educated about hand soap, lotion, makeup and eye cream. In addition to the measures discussed above, they can moisten a cotton swab or plunger with lubricant or conditioner and clean the surface of the lens on the eye.

Fogging, debris and wetting issues are popular ocular surface problems that plague scleral lens patients. Debris builds up when a poor fit pulls in tear layer lipids; it can be resolved by adjusting the fit to eliminate lens movement and tear exchange. Also, a tight lens with excessive limbal clearance may cause limbal congestion and inflammation. The latter is resolved by treating the inflammation and underlying disease prior to fixing the fit in an effort to improve the



This scleral has poor wettability and a buildup of material on its front surface.

quality of the lipid secretions from the lids.

Conjunctival prolapse is another scleral complication to watch out for. This occurs due to eyelid pressure and gravity pulling the lens down, with elevation differences creating greater vault at the inferior cornea

and limbus, creating the perfect space for loose conjunctiva to collect. To resolve this issue, reduce limbal clearance if possible, switch to a toric- or quadrant-specific design, and reduce suction when applicable.

Conjunctival hypertrophy, on the other hand, results from an edge that is too tight and compresses/impinges the conjunctiva locally. Toric haptics, notching, microvaults and freeform lens designs can all reduce the incidence.

“Someday when I retire and sit back and think about my life in optometry, of my 100 best moments in my life, 90-some will be related to a scleral lens because of the difference they make,” Dr. Jedlicka concluded. “The life-changing stories that I have accumulated—that’s what I will remember.” ■

Set Your Eyes on Outside-the-Classroom Education

Earn free CE credits and gain valuable information right on the show floor! All courses are for CE credit unless otherwise noted on the schedule. The Presentation Theater courses are open seating and registration is not required, first come will be first admitted. Limited seating available.

Friday, April 30

200: Evidence-based Scleral Lens Management, *Maria Walker, OD*

201: Modern Aesthetics for the Optometric Physician, *Chris Wroten, OD*

Saturday, May 1

202: A Patient Management Perspective on Dry Eye Disease, *Ron Melton, OD, and Randall Thomas, OD*

203: New Treatment Options for Patients with Acquired Blepharoptosis, *April Jasper, OD*

NEW ORLEANS
MARCH 9-12
 ERNEST N. MORIAL CONVENTION CENTER

SECO 2022
 WHERE SIGHT MEETS VISION™



A NEW WAY TO EXPERIENCE REVIEW OF OPTOMETRY

Follow us on Instagram at @revoptom for striking clinical images, daily news headlines, issue previews and great content from the magazine—all formatted for mobile



REVIEW OF OPTOMETRY
NEWS FEED • THE NEWS FEED • THE NEWS FEED • THE NEWS FEED • THE NEWS FEED

Stories for 3-26-21

Missed Neuro Diagnoses Common, Can Lead to Patient Harm
Study finds half of all referrals were incorrect and one in four of those experienced some kind of adverse impact on health.

CDC Aims to Break Down Telemed Barriers in Glaucoma
Three universities get funding for a five-year investigation into the logistics and clinical value of remote screenings.

Thyroid Eye Disease Increases Risk of Optic Nerve Damage
Affected eyes experience thinning of the RNFL and ganglion cell layer, increasing the likelihood of progression to subclinical optic neuropathy.

Read today at www.reviewofoptometry.com/news

REVIEW OF OPTOMETRY

High myopia with a tessellated and thin choroid (red line), RPE disruption (gray line), SRF (yellow line), RPE (green line) elevations/photoreceptors (blue line) with early subretinal and hyperreflective material (purple line)—all consistent with myopic DNV.

Chorioid folds causing sub-RPE undulations (red lines).

From "Take Macular OCT to a Whole New Level," by Sara Waldman, OD
Available at www.reviewofoptometry.com/issue/february-19-2021

REVIEW OF OPTOMETRY

DRY EYE READER SURVEY RESULTS

What percent of your patients in each of these categories suffers from dry eye?

Category	0%	10%	20%	30%	40%	50%	60%	70%
Adolescents and teens								
Adults 20-40 years old								
Adults 41-60 years old								
Adults 61 and older								
Contact lens wearers								
Men								
Women								
Post-menopausal women								

From "Dry Eye in Oculometry: Trends, Habits and Hints," by Paul E. Hammond, OD
Available at www.reviewofoptometry.com/issue/january-15-2021

REVIEW OF OPTOMETRY

Redness associated with a subconjunctival hemorrhage.

From "The Eye Remembers: How and Which-Test," by Julie Tyler, OD, and Dr. Peter Lovell, OD
Available at www.reviewofoptometry.com/issue/november-15-2020

REVIEW OF OPTOMETRY

CLINICAL FEATURES OF COMMON SECONDARY CONDITIONS ASSOCIATED WITH GLAUCOMA

CONDITION	SLT LAAP FEATURES	ENDOSCOPIC FEATURES
Pigment dispersion syndrome	Pigment deposition on anterior segment structures (eg, anterior lens surface and optical axis)	Active stage: dense homogeneous apposition of the anterior angle Inactive stage: pigment overgrowth Inactive angle appears more pigmented, thereby obliterating angle
Pseudoexfoliative syndrome	Extensive fibrillar material deposition on anterior segment structures (eg, anterior lens surface, endothelium, iris, and cornea endothelium) Pseudoexfoliation (transient/exfoliation) Pseudoexfoliation	Deposition of extracellular material in anterior chamber angle Increased angle pigmentation of the trabecular meshwork
Interior segment inflammation	Anterior chamber cells or flare Endothelial leukocytarion Pseudoexfoliation	Pseudoexfoliation Pseudoexfoliation
High myopia	Sub-threshold bullous and/or acute inflammation High myopia, myopia, pseudoexfoliation, subluxation, subluxation, or subluxation	Widening of the ciliary body band Widening of the ciliary body band Irregular hyperpigmentation of the angle Apposition of the ciliary body band to the trabecular meshwork
Neovascularization	High myopia	Neovascularization within the angle

From "Glaucoma: Shorter RT: Case Up for Clinical Care," by Jack Pao, OD, PhD, and Kenneth Wong, OD, OD
Available at www.reviewofoptometry.com/issue/march-15-2021

REVIEW OF OPTOMETRY

RETINA QWZ: A 22-year-old white female high myope presented with blurred vision, OD-OS, for over six months, and said she felt like there was a "dead spot" in her central vision. Medical history was significant for Crohn's disease since age 14, which had a recent flare-up. BCVA measured 20/400 OD with eccentric viewing and 20/190 OS. Amlier grid showed a central scotoma in both eyes but was very dense OD. There was slight inversion of both optic nerves. She had a myopic-appearing fundus, and other significant changes noted above. See full for OCT scans.

From "Dead Spot," by Eric Dilling, OD, edited by Mark Jankov, OD
Available at www.reviewofoptometry.com/issue/march-15-2021

REVIEW OF OPTOMETRY

MAR 2021

Dry Eye Issue

AVAILABLE MARCH 15 AT www.reviewofoptometry.com

REVIEW OF OPTOMETRY

CLINICAL QUANDARIES: A 57-year-old female presented with a red eye, a painful eye of the lower lid and eyelids. What do you think is happening and how would you treat it? (Click left for a second image about the diagnosis and management plan.)

From "Clinical Quandaries," by Paul E. Hammond, OD
Available at www.reviewofoptometry.com/issue/march-15-2021

REVIEW OF OPTOMETRY

Macular Thickness - Macular Cube 20x200

The warmer colors on this macular OCT indicate edema. Since the result is consistent with the classic pattern of inner retinal edema and mild outer retinal shadowing seen in acute artery occlusions, the patient was diagnosed with a bilateral artery occlusion (BLAAO).

From "The Eye Remembers," by Paul Hammond, OD
Available at www.reviewofoptometry.com/issue/march-15-2021

REVIEW OF OPTOMETRY

Additional studies that might yield diagnostically pertinent data:
• 30-2 to look for peripheral constriction
• ERG and dark adaptation testing for rod function suppression

From "The Eye Remembers," by Paul Hammond, OD
Available at www.reviewofoptometry.com/issue/march-15-2021



REVIEW OF OPTOMETRY

An 81-year-old man presented complaining of a new "fish-chaper" floaters OS. Searching it is constant and stationary. The macula shows a small demarcated area of whitening.

From "Fish Out of Water," by Paul Hammond, OD
Available at www.reviewofoptometry.com/issue/march-15-2021

REVIEW OF OPTOMETRY

Diffuse choroidal staining with fluorescein in a patient with severe dry eye and a history of RR.

From "Don't Let RRID Compromise Contact Lens Success," by Anne Francis, OD
Available at www.reviewofoptometry.com/issue/march-15-2021

REVIEW OF OPTOMETRY

FAST FACTS ON CLRAO

- only present in approximately one in three people
- provides a secondary blood supply to the inner layers of the macula
- comprises only 3.3% to 7.3% of all retinal artery occlusions
- has been associated with embolism, lupus, antiphospholipid syndrome, sickle cell, pregnancy and systemic hypertension
- can present in three ways: (1) with ischemic optic neuropathy in giant cell arteritis, (2) with concomitant central retinal vein occlusion or (3) in isolation

Management and prognosis:
• OCA: Critical to arrange for same-day ESR and CRP testing and begin IV steroid. Visual prognosis is the worst of the three due to lack of redundant circulation.
• CRVO: Treatment focuses on macular edema and macular traction. Better prognosis, as the vein occlusion tends to be non-ischemic.
• If isolated: Treatments can include ocular massage, paracentesis, intra-arterial thrombolysis and hyperbaric oxygen. Best visual prognosis.

CASE OUTCOME
This patient's case was deemed likely retinal and involved in nature. The SFA defect persisted, but his vision remained 20/20 and the symptoms were not as bothersome.

From "Fish Out of Water," by Paul Hammond, OD
Available at www.reviewofoptometry.com/issue/march-15-2021

REVIEW OF OPTOMETRY

Blurred then photopsia in a 31-year-old Hispanic male.

Peripapillary retinitis with a conjunctival discharge was recommended in the right eye (hs) secondary to the degree of involvement on the line of sight and conjunctival-related conjunctival inflammation.

From "The Eye Remembers," by Paul Hammond, OD
Available at www.reviewofoptometry.com/issue/march-15-2021

REVIEW OF OPTOMETRY
NEWS FEED • THE NEWS FEED • THE NEWS FEED • THE NEWS FEED • THE NEWS FEED

Stories for 3-26-21

Missed Neuro Diagnoses Common, Can Lead to Patient Harm
Study finds half of all referrals were incorrect and one in four of those experienced some kind of adverse impact on health.

REVIEW OF OPTOMETRY

From "The Eye Remembers," by Paul Hammond, OD
Available at www.reviewofoptometry.com/issue/march-15-2021

REVIEW OF OPTOMETRY

ANTERIOR SEGMENT FACTORS IN GLAUCOMA

From "The Eye Remembers," by Paul Hammond, OD
Available at www.reviewofoptometry.com/issue/march-15-2021

REVIEW OF OPTOMETRY

From "The Eye Remembers," by Paul Hammond, OD
Available at www.reviewofoptometry.com/issue/march-15-2021

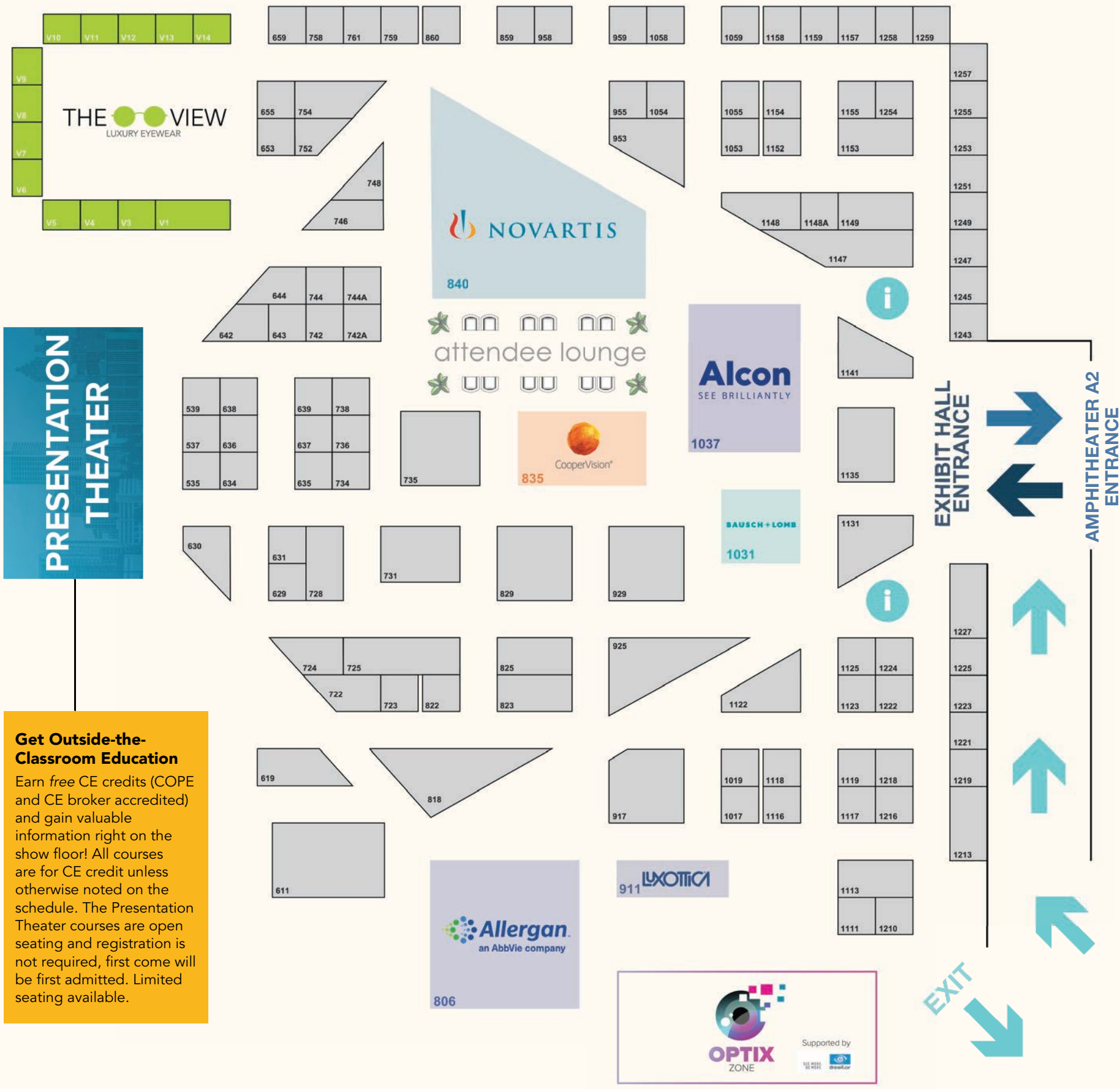

EXHIBITOR BOOTH LISTINGS FOR SECO 2021

Optometry's Marketplace™ puts you in the same room with leading suppliers offering brands representing everything you need to keep your practice on the cutting edge. Through integrated learning, discover the technology, equipment and services that will help you create an exceptional experience for your patients and run a more profitable practice.

ACEP USA.....	1019	MacuLogix	635
Acculens	1149	MedTech International Group.....	736
Aerie Pharmaceuticals	1227	Modern Optical International	958
Alcon	1037	MyEyeDr	917
Allergan	806	National Academy of Opticianry.....	1210
American Association of Corporate Optometrists	1225	Next Vision Instruments	539
American Board of Opticianry & National Contact Lens Examiners	1111	Nidek.....	742A
American Board of Optometry	1123	Notal Vision	955
Arbor Eyewear.....	1053	Novartis Pharmaceuticals.....	840
Armed Forces Optometric Society.....	637	Oasis Medical.....	722
Avellino Labs.....	731	Ocular Innovations.....	953
Bausch + Lomb.....	103	Oculus	636
BlephEx.....	759	Olleyes.....	859
Bruder Healthcare Company.....	653	Opticians Association of Georgia	1118
Coburn Technologies.....	1249	Opticam Tech	1148
Compulink Healthcare Solutions.....	929	Optometric Architects	629
CooperVision	835	Optos.....	1153
Design Eyewear Group.....	V14	Optovue	638
DGH Technology	1059	Orgreen Goldsmith.....	V8
Digital Healthcare Professionals	738	Ottica Venets IISospriri Eyewear	V3
Diopsys.....	1058	Enhanced Therapy USA	1254
Doctor Multimedia	1131	Pharmanex/MD Solution.....	644
Eastern Ophthalmic Supply & Repair.....	1147	qPlusoptix	1222
Edison Optics	752	Poets Eyewear.....	V4
eSee Acuity	1154	Popsharp.....	754
Etnia Barcelona	V1	Premier Ophthalmic Services	642
Eventsphere	1213	Quantel Medical	634
Ye Designs	825	Remote Area Medical.....	1251
Eyefficient.....	744A	Review of Optometry	611
Eyefunc.....	631	RVL Pharmaceuticals	73
Eyes of Faith	734	Salt.....	V6
Eyevance Pharmaceuticals.....	1141	Santinelli International	1125
Falck Medical	860	Scleral Lens Education Society.....	1221
Faniel Eyewear	V10	Scope Eyecare.....	1224
FCI Ophthalmics	1223	Scratchpay.....	1117
Fusion Eyewear	V12	Opticwash	1116
Gazal Eyewear.....	V9	Sight Sciences.....	619
Heidelberg Engineering.....	1243	Kodak Lens/Signet Armorlite	724
Heine	535	Simplifeye.....	639
Henau Eyewear	V7	Southern College of Optometry.....	823
Icare USA	1122	Studio Optyx.....	V13
Idealoptics	1017	Sun Ophthalmics	818
Innovative Technology Solutions of NC.....	537	TelScreen.....	742
Invision Magazine	1219	The Dry Eye Doctor.....	744
Jeunesse Innovations	1155	ThermaMedx	925
Kala Pharmaceuticals	1113	Topcon Healthcare	1135
Karl-Optical Distribution.....	655	Vision Center South	643
Kasperek USA Optical	822	Visual Inspirations	V11
Kids Bright Eyes	723	VOSH International.....	1148A
Lands' End Business Outfitters.....	1247	Walman.....	630
Luxottica Group	911	Wolters Kluwer	1245
MacuHealth.....	728	Zeiss.....	829

FRIDAY, APRIL 30 ~ EXHIBIT HALL OPENS 9am, CLOSES 5pm



PRESENTATION THEATER

Get Outside-the-Classroom Education
 Earn free CE credits (COPE and CE broker accredited) and gain valuable information right on the show floor! All courses are for CE credit unless otherwise noted on the schedule. The Presentation Theater courses are open seating and registration is not required, first come will be first admitted. Limited seating available.

FRIDAY AT A GLANCE

OD & AHP ADVANCED LEARNING COURSES (SHADED IN GREEN) HAVE VARIOUS ACCREDITATIONS BASED ON CONTENT, AND THE ACCREDITATION INFORMATION IS LISTED FOR EACH COURSE BELOW.

7:00 AM	125 Important Lab Testing in Optometry 7:00 AM-8:00 AM Room A411/412 Caroline Pate, OD	510 OD & AHP Advanced Getting Started with OCT 7:00 AM-8:00 AM Room A311/312 & Streaming Julie Rodman, OD		
7:15 AM				
7:30 AM				
7:45 AM				
8:00 AM	061 OD & AHP Advanced SPECIAL SESSION - Clinical Perspectives In Patient Care 8:00 AM-10:00 AM Amphitheater A2 & Streaming Ron Melton, OD Randall Thomas, OD			
8:15 AM				
8:30 AM				
8:45 AM				
9:00 AM				
9:15 AM				
9:30 AM				
9:45 AM				
10:00 AM	200 FREE OD Presentation Theater Evidence-based Scleral Lens Management 10:00 AM-11:00 AM Exhibit Hall Presentation Theater Maria Walker, OD		205 Managing Patient Issues 10:00 AM-11:00 AM Exhibit Hall OPTIX Zone Brooke Carrasco	
10:15 AM				
10:30 AM				213 Sell \$1000 Frames on a Daily Basis 10:30 AM-11:00 AM Exhibit Hall The View Andy Tabrizipour
10:45 AM				
11:00 AM	127 Ocular Effects of Systemic Medications 11:00 AM-12:00 PM Room A313/314 Nate Lighthizer, OD	128 Beauty and the Beast 11:00 AM-12:00 PM Room A311/312 & Streaming Leslie Odell, OD	129 Nutrition and the Retina 11:00 AM-12:00 PM Room A305 Steven Ferrucci, OD	130 Comprehensive Management of the Patient with Keratoconus 11:00 AM-12:00 PM Room A302 Jason Jedlicka, OD
11:15 AM				
11:30 AM				
11:45 AM				
12:00 PM	305 FREE LUNCH OD Lunch Symposia Precision1® Your Go-To Lens With Innovative Water Surface Technology, Chris Lievens, OD, presented by Alcon Connecting the Dots, Whitney Hauser, OD, presented by Novartis 12:00 PM-1:00 PM Amphitheater A2			723 Multifocal Contacts: How To Make Them Work 12:00 PM-1:00 PM Room A313/314 Mile Brujic, OD
12:15 PM				
12:30 PM				
12:45 PM				
1:00 PM	PRESENTATION THEATERS			
1:15 PM	EARN FREE CE CREDITS AND GAIN VALUABLE INFORMATION IN OPTOMETRY'S MARKETPLACE™.			
1:30 PM				
1:45 PM				
2:00 PM				
2:15 PM	131 Ocular Trauma 2:15 PM-4:15 PM Room A411/412 Michelle Welch, OD	132 Dry Eye and Contact Lenses 2:15 PM-4:15 PM Room A313/314 Leslie Odell, OD	134 Innovations in Glaucoma: Next Generation Technology, Medications, and Delivery 2:15 PM-4:15 PM Room A311/312 & Streaming Justin Schweitzer, OD	135 The Retina: New Solutions to Old Problems 2:15 PM-4:15 PM Room A302 Alexander Bottini, MD
2:30 PM				206 Managing Made Easy 2:15 PM-3:15 PM Exhibit Hall OPTIX Zone Ryan Parker, OD
2:45 PM				
3:00 PM				727 Ocular Anatomy for Techs and Opticians 3:15 PM-4:15 PM Room A404/405 Rebecca Johnson
3:15 PM				
3:30 PM				
3:45 PM				
4:00 PM				
4:15 PM	OPTOMETRY'S MARKETPLACE™ DISCOVER EFFICIENCY-ENHANCING SOLUTIONS, STATE-OF-THE-ART EQUIPMENT, FASHIONABLE EYEWEAR STYLES, AND INTERACTIVE EDUCATIONAL EVENTS AS FAR AS THE EYE CAN SEE - ALL ON THE SHOW FLOOR.			
4:30 PM				
4:45 PM				
5:00 PM	4/30 9:00 AM-5:00 PM 5/1 9:00 AM-4:00 PM		PRESENTATION THEATER THE VIEW OPTIX & OD LOUNGE	207 Oakley Prizm Lenses 4:15 PM-5:15 PM Exhibit Hall OPTIX Zone Jonathan Smith
5:15 PM	140 Diseases of the Vitreomacular Interface 5:15 PM-7:15 PM Room A313/314 Julie Rodman, OD	137 Laser Therapy and Advanced Procedures in Optometry 5:15 PM-7:15 PM Room A311/312 & Streaming Nate Lighthizer, OD	138 Frontline Ocular Surface Disease Care 5:15 PM-7:15 PM Room A411/412 Paul Karpecki, OD Justin Schweitzer, OD	139 Retinal and OCT Grand Rounds 5:15 PM-7:15 PM Room A302 Steven Ferrucci, OD
5:30 PM				
5:45 PM				
6:00 PM				
6:15 PM				
6:30 PM				
6:45 PM				
7:00 PM				
7:15 PM				
7:30 PM				
7:45 PM				





OPTOMETRY'S MARKETPLACE™ 9:00AM-5:00PM







SECO's comprehensive program offers more than 70 educational courses throughout the conference.

For course descriptions and the entire five-day education program, visit attendseco.com/education.

Here are today's courses for optometrists and allied health professionals.

Missed a course at SECO 2021? Log on to secouniversity.com throughout the year to access all courses.

-  OD-ONLY COURSES
-  ALLIED HEALTHCARE PROFESSIONALS-ONLY COURSES
-  OD & AHP ADVANCED COURSES
-  MedPRO360 COURSES

-  ABO
-  AOA Paraoptometric
-  Treatment & Management of Ocular Disease: Anterior Segment
-  Florida CE Broker (live only)
-  CEE/TQ Course (live only)
-  Contact Lenses

7:00 AM	720 Contact Lens Solutions for Dry Eye 7:00 AM-8:00 AM Room A315/316 & Streaming <i>Mile Bruijic, OD</i>				
7:15 AM					
7:30 AM					
7:45 AM					
8:00 AM	721 Rebuilding: Bolster Morale, Reduce Anxiety, and Enhance Safety for Your Team and Patients 8:00 AM-10:00 AM Room A311/312 & Streaming <i>Lynn Lawrence</i> <i>Sharon Carter</i> <i>Joy Gibb</i>	511 Facilitated Learning Lab Coding and Billing Patient Communication Strategies 8:00 AM-10:00 AM Room 402/403 <i>Chris Wolfe, OD</i>			
8:15 AM					
8:30 AM					
8:45 AM					
9:00 AM					
9:15 AM					
9:30 AM					
9:45 AM					
10:00 AM	OPTOMETRY'S MARKETPLACE™ DISCOVER EFFICIENCY-ENHANCING SOLUTIONS, STATE-OF-THE-ART EQUIPMENT, FASHIONABLE EYEWEAR STYLES, AND INTERACTIVE EDUCATIONAL EVENTS AS FAR AS THE EYE CAN SEE - ALL ON THE SHOW FLOOR.		PRESENTATION THEATERS EARN FREE CE CREDITS AND GAIN VALUABLE INFORMATION IN OPTOMETRY'S MARKETPLACE™.		
10:15 AM					
10:30 AM					
10:45 AM					
11:00 AM	304 FREE LUNCH AHP Lunch Symposia Refresh®: Advancements in Care for Patients With Eye Dryness , <i>Marc Bloomenstien, OD, FAAO</i> , presented by Allergan The Toric Lens Opportunity , <i>Steve Rosinski, OD</i> , presented by CooperVision 11:00 AM-12:00 PM GWCC Room A411/412				
11:15 AM					
11:30 AM					
11:45 AM					
12:00 PM	724 The Optical World of 3D Printing...Frames and Lenses 12:00 PM-1:00 PM Room A404/405 <i>Laurie Pierce</i>	415 MedPRO360 Communicating with Patients 12:00 PM-1:00 PM Room A311/312 & Streaming <i>Sharon Carter</i>	305 FREE LUNCH OD Lunch Symposia Precision1® Your Go-To Lens With Innovative Water Surface Technology , <i>Chris Lievens, OD</i> , presented by Alcon Connecting the Dots , <i>Whitney Hauser, OD</i> , presented by Novartis 12:00 PM-1:00 PM GWCC Amphitheater EH A2		
12:15 PM					
12:30 PM					
12:45 PM					
1:00 PM					
1:15 PM	726 Theory of Refraction 1:15 PM-2:15 PM Room A315/316 & Streaming <i>Phernell Walker</i>	416 MedPRO360 Maximizing Message Boards and Social Media Groups 1:15 PM-2:15 PM Room A411/412 <i>Darryl Glover, OD</i>	201 FREE OD Presentation Theater Modern Aesthetics for the Optometric Physician 1:00 PM-2:00 PM Exhibit Hall Presentation Theater <i>Chris Wroten, OD</i>		
1:30 PM					
1:45 PM					
2:00 PM					
2:15 PM					
2:30 PM					
2:45 PM					
3:00 PM					
3:15 PM	728 The Optics of Strong Lenses 3:15 PM-4:15 PM Room A305 <i>Laurie Pierce</i>	417 MedPRO360 Tele-Frame Styling & Optical Sales 3:15 PM-4:15 PM Room A315/316 & Streaming <i>Joy Gibb</i>			
3:30 PM					
3:45 PM					
4:00 PM					
4:15 PM	730 AHP General Session How to Deliver a Patient Centric Eyecare Experience in 2021 and Beyond 4:15 PM-6:15 PM Amphitheater A2 & Streaming <i>Ryan Parker, OD</i> <i>Pete Hanlin</i> <i>Sharon Carter</i> <i>Frank Pigner</i>				211 Frame Fashion Tour I 4:30 PM-5:00 PM Exhibit Hall The View <i>Laurie Pierce</i>
4:30 PM					
4:45 PM					
5:00 PM					
5:15 PM					
5:30 PM					
5:45 PM					
6:00 PM					
6:15 PM					
6:30 PM	AHP Party supported in part by Essilor 6:30 PM-8:15 PM OMNI International Ballroom				
6:45 PM					
7:00 PM					
7:15 PM					
7:30 PM					
7:45 PM					

OPTOMETRY'S MARKETPLACE™ 9:00AM-5:00PM

- Ethics/Jurisprudence
 - Glaucoma
 - General Optometry
 - Injection Skills
 - Laser Procedures
 - NCLE
- Neuro-Optometry
 - Oral Pharmaceutical
 - Principles of Diagnosis
 - Pharmacology
 - Practice Management
 - Peri-Operative Management of Ophthalmic Surgery
- Treatment & Management of Ocular Disease: Posterior Segment
 - Refractive Surgery Management
 - Systemic/Ocular Disease
 - Surgical Procedures
 - Functional Vision/Pediatrics
 - Public Health
- Low Vision/Vision Impairment & Rehabilitation
 - Facilitated Lab/Workshop
 - Virtual Session
 - Food Course

* Brought to you by the National Academy of Opticianry

Healthy Debates Move the Profession Forward

A look at current controversies in medical and surgical eye care, and the best way to handle them.

When one says the field of optometry has evolved in numerous ways, you could automatically think of the new treatments and advancements in technology. But it has also evolving by adding some challenges and controversies when it comes to the surgical side of eye care.

“As we’ve evolved from directing medical care to diagnosing it and treating it, we also had to add new decision-making skills—specifically, how do we manage uncertainty?” said Brooks Alldredge, OD, of Pacific Cataract and Laser Institute in a talk yesterday morning. “Our most challenging problems often require doing something even when we aren’t positive of the diagnosis or management plan. We still have to act somehow.”

In his lecture, Dr. Alldredge talked about how, over time, he’s become less interested in what’s right and wrong in certain situations and more into “what works,” leaning in to a more pragmatic way of thinking.

“A smart teacher of mine once said, ‘There are simply wrong ways of doing things but usually multiple right ways,’” he recalled. “Still, in caring for a specific patient, we have to pick one amongst other choices yet remain humble in that the alternatives can be valid as well. Knowing the difference between a strongly held opinion and evidence, the latter provides little more than likelihoods and probabilities and rarely exact instructions as to what to do.”

Dr. Alldredge gave his perspective when addressing certain controversies in medical and surgical eye care, such as same-day bilateral cataract surgery, for example. The first argument in favor, not surprisingly, is patient convenience.

“It’s not a value we can ignore,” he said. “There’s only one trip to the operating room. With the current staggered approach, ‘we’re having a number of trips we need to make for each patient, assuming they are having bilateral surgery.’”

Fewer follow-up exams and less downtime are other benefits to having bilateral surgery, as well as more surgical appointments available for more patients.

The chief argument against same-day surgery is risk of infection. “To have any infection is a disaster. The potential of infection with two eyes is a catastrophic beyond measure,” said Dr. Alldredge. If it occurred in a measurable basis for elective surgery, it would lead to immediate discontinuance, he suggested.

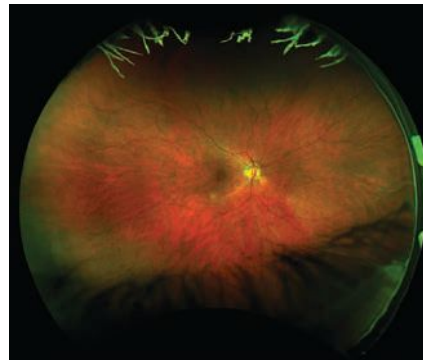“Monocular incidence is still low, at 0.04 to 0.02,” he added. “In my practice amongst 17 offices—we’re the second largest cataract practice in the country—we do about 40,000 total surgeries in a year. When you do the math, you’re still talking about seven or eight cases of infection on a normal basis. Each one of those we take incredibly seriously.”

Another argument is the drastic reduction in reimbursement. “Reimbursement for bilateral surgery is 50%, even though you’d done two identical operations on the same day. If you wait one more day, you get paid the whole amount. It’s a business, and surgery centers have to think about these things.”

Dr. Alldredge also put a new spin on the debate over widefield imaging, saying that it improves every year and it’s here to stay. Arguments for its use include the claim that it may be up to 30% better at discovering peripheral lesions.

“That’s important because those are the things that we worry about missing or need to identify that could potentially cause retina detachment,” he said. “You can see the retina in one image and have simultaneous presentation, which is something I think we lost with EMR,” he said.

Arguments against include a poor exam of the vitreous, an undilated, undiagnosed retinal disease being a leading source of optometric malpractice and a high number of artifacts resulting in unnecessary referrals.



The debate over widefield imaging highlights its utility in discovering peripheral lesions.

“There’s evidence of over-referral of patients based solely on finding an artifact,” Dr. Alldredge says. “Optos may be 30% more sensitive at identifying peripheral lesions, but it may actually be poor at identifying retina holes in retina breaks in the areas we

had the most concern that lead to retinal detachment.”

Although Dr. Alldredge says uncertainty hasn’t necessary grown over the years, it’s still something eyecare professionals deal with while facing certain situation, and he hopes attendees left with a better sense of decision-making.

“What I try to do in these lectures is say it’s ok not to feel like you know exactly what’s happening, but ultimately you have to have strategize to make a decision. That’s what this is all about.”

His talk also delved into the need for macular OCT prior to cataract surgery, anti-VEGF in non-symptomatic DME and whether OCT angiography is making fluorescein angiography obsolete—all rich areas of debate and, ultimately, evolution. ■

Where Things are Headed in Glaucoma Care

GLAUCOMA, continued from Page 1

Despite the new additions, drops still pose perennial issues with compliance, adherence, pharmacokinetics and side effects, Dr. Yadgarov explained.

Beyond the Bottle

For patients who prefer to be drop-free, numerous alternatives are available, and some older techniques are getting good marks in recent literature.

Although selective laser trabeculoplasty (SLT) has been around since 2001, a new investigation, the LIGHT study, found very favorable results for SLT when compared to prostaglandins as a first-line therapy in treatment-naïve patients. While IOP lowering was similar between the two groups and both achieved the target goal, 11 patients underwent glaucoma surgery in the medication group vs. zero in the SLT group at three years.

Other new techniques include micropulse cyclophotocoagulation, a procedure that “tickles the ciliary body,” Dr. Yadgarov said, and is thought to induce cytokine release that increases uveoscleral outflow. He described the non-invasive procedure as very safe, with no significant side effects. Dr. Yadgarov recommends cyclophotocoagulation in individuals who are afraid of surgery, high-risk, elderly, frail or in individuals who had previously failed procedures.

Another recent implant addition is Durysta (Allergan), a dissolvable pellet of 10mcg bimatoprost placed intracamerally. Although it’s currently approved for one administration only, this option is safe,



Photo: Rachel Gaywood, OD

iStent inject insertion directly following cataract surgery is increasingly common.

low risk, painless and can be done at a slit lamp. Good candidates would be those with dexterity issues, ocular surface disease patients, forgetful individuals who struggle with medication compliance and those with poor SLT response. Dr. Yadgarov suggested avoiding this in prostaglandin-contraindicated cases or in anyone with a bad reaction to the drug class (other than conjunctival injection).

MIGS have also made huge strides in recent years, Dr. Yadgarov said. Some new techniques include the iStent Inject (Glaukos) and Hydrus Microstent (Ivantis). Both have similar postoperative outcomes and safety profiles, and roughly 75% patients will achieve a 20% IOP reduction at two years. The Hydrus has slight superiority over iStent when compared to their respective controls. If implanted correctly, either of these options could get patients off one to two meds, with an 80% chance of removing one drop from the regimen for up to two years (potentially up to five years for Hydrus).

Other new glaucoma surgery options discussed in the session include goniotomy/trabeculotomy, canaloplasty and the Xen gel stent (Allergan).

The Xen offers a completely different form of surgery, Dr. Yadgarov said, since it creates a new drain. The gelatin stent diverts fluid from the anterior chamber to the subconjunctival space. Compared with trabeculectomy and conventional tube shunts, the Xen has a much quicker recovery period, less intense postoperative management. It’s so ubiquitous, he said, that it’s

becoming the “phaco” of glaucoma surgery. Most patients can resume normal life one to two days post-op. The technique doesn’t require sutures and vision generally returns to normal by day two.

Dr. Yadgarov concluded by explaining that the end goal of glaucoma management should be to provide therapy for patients that doesn’t significantly affect their quality of life, avoids lifelong, costly daily medications, stabilizes the disease without relying heavily on patient adherence and avoids exacerbating underlying dry eye. ■

DOWNLOAD THE SECO APP

Download the SECO 2021 Mobile App for course details, personalized schedule, exhibitor information and more!

- COURSE DESCRIPTIONS
- COURSE HANDOUTS
- SPEAKER BIOS
- VIRTUAL COURSE LISTINGS
- VOA ACCESS
- ENHANCED EXHIBITOR LISTINGS
- MARKETPLACE MAP AND EASY COMPANY LOCATOR
- SOCIAL MEDIA INTEGRATION
- NETWORKING: CONNECT, MESSAGE, CHAT, AND SCHEDULE MEETINGS WITH COLLEAGUES







Supported in part by



REMAINING SECO 2021 CEE TQ COURSES

Friday, April 30

- 2:15pm–4:15pm: Course 131, Ocular Trauma, Michelle Welch, OD
- 5:15pm–7:15pm: Course 138, Frontline Ocular Surface Disease Care, Paul Karpecki, OD, Justin Schweitzer, OD
- 5:15pm–7:15pm: Course 139, Retinal and OCT Grand Rounds, Steven Ferrucci, OD

Saturday, May 1

- 4pm–6pm: Course 154, Lumps and Bumps, Michelle Welch, OD
- 4pm–6pm: Course 155, Following AMD with OCT, Julie Rodman, OD

While You Were Sleeping: OSA and the Eye

This all-too-common condition can expose patients to a number of ocular complications.

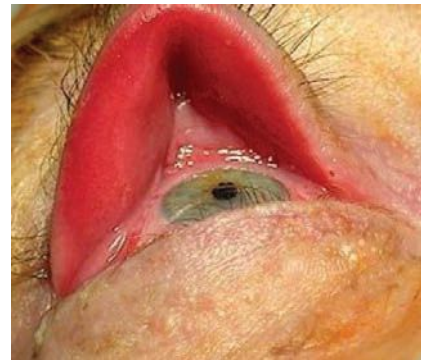
Tammy Than, OD, jumped right into her course, “The Vision and Wellness Connection,” yesterday afternoon with a discussion of obstructive sleep apnea (OSA). In this particular form, a patient’s throat muscles intermittently relax and block their airway while they’re sleeping. As a result, breathing stops involuntarily for brief periods of time during sleep and snoring occurs.

Risk factors for OSA include children with large tonsils and adenoids, men with a collar size greater than 16 in., women with a collar size greater than 15 in., a large tongue, a shorter lower jaw than the upper jaw, a narrow palate or airway that collapses more easily and obesity. Obesity is also a risk factor for cataract, glaucoma, diabetic retinopathy and macular degeneration.

Symptoms of the condition are as follows: excessive daytime sleepiness, loud snoring, abrupt awakenings accompanied by gasping or choking, awakening with a dry mouth or sore throat, morning headache, difficulty concentrating during the day, mood changes (e.g., depression, irritability), nighttime sweating and decreased libido.

As it pertains to the eye, OSA is associated with floppy eyelid syndrome, non-arteritic anterior ischemic optic neuropathy, central serous retinopathy, retinal vein occlusion and glaucoma.

Floppy lid syndrome secondary to OSA is bilateral but asymmetric. The condition reduces the elastin of the tarsal plate and may cause eyelash ptosis. It commonly occurs in overweight, middle-aged males and has also been linked to keratoconus and meibomian gland dysfunction.



Obstructive sleep apnea is associated with floppy eyelid syndrome, which can present obstacles to successful cataract surgery.

Risk factors for development of OSA include genetics, lifestyle, medications, certain diseases, social and economic issues, and age.

Signs and symptoms include ocular irritation, unsuccessful treatment of ocular irritation, a rubbery and easily everted upper tarsal plate,

mucoid discharge, conjunctival injection, papillary conjunctivitis of the upper lid and a pupil centered near the maximally elevated upper eyelid.

To manage floppy lid syndrome, consider ocular lubrication, secondary infection treatment, shield or lid taping, surgery in severe cases, doxycycline for six to 12 weeks, obstructive sleep apnea treatment and weight loss.

Dr. Than wrapped up the lecture by encouraging attendees to take a deep dive into the lifestyle changes patients may benefit from, as genetics only contribute to a small part of risk for many diseases. Educating patients and helping them take the steps needed to implement certain changes, such as to their diet and lifestyle, may make a world of difference in their overall and ocular health. ■

Viral Ocular Infections: Addressing an Epidemic

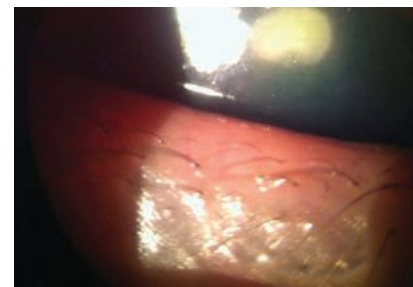
GOING VIRAL, continued from Page 1

Dr. Lighthizer cautioned to pay attention to anterior uveitis as it will have short- and long-term effects on the patient, namely bumping up IOP. Regarding oral antivirals, he noted Valtrex (valacyclovir, GlaxoSmithKline) 1000mg three times a day for seven to 10 days receives better patient compliance due to fewer doses per day. Dr. Lighthizer advised having patients on antivirals within a window of 72 hours of symptoms. “The earlier they are on antivirals, the better,” he recommended. Nevertheless, valacyclovir and famciclovir were proven to do better outside the 72-hour window.

A brief discussion on the Shingrix (glycoprotein E, GlaxoSmithKline) and Zostivax (live-attenuated vaccine, Merck) vaccines followed the case, as Dr. Lighthizer noted Shingrix’s efficacy in younger patients and role in preventing post-herpetic neuralgia.

Atypical Cases

Dr. Lighthizer’s second case was an epidemic keratoconjunctivitis case in a 27-year-old with a photosensitive, red eye who had visited his office four times previously to have pseudomembranes removed. He reviewed the “rule of sevens or eights” regarding the time course of EKC—an average of 18 to 24 days. He also noted that he now uses a Q-tip soaked in phenylephrine to peel pseudomembranes. This patient’s EKC was so bad that Dr. Lighthizer had to remove a pseudomembrane from the upper lid with forceps. He recommended Betadine 5% ophthalmic solution (povidone-iodine, Avrio Health) and possibly steroids afterwards for infiltrates and pseudomembranes. “Although it will still be irritating for a patient with early EKC, Betadine can shorten the course significantly, which can be noticeable within 48 to 72 hours,” he explained.



This pseudomembrane in the left lower fornix of an EKC patient is being peeled with a cotton tip applicator.

The third case involved a 34-year-old female contact lens wearer with a peripheral corneal infiltrate at the limbus. However, the case was not lens-related but rather an atypical herpes simplex presentation. A mild acute uveitis again brought simplex and zoster back to the differential. Dr. Lighthizer provided the audience with a tip on using corneal sensitivity alongside measuring IOP to assist in making the diagnosis. He uses dental floss to test it himself, as he

finds it more consistent when making a baseline in the unaffected eye.

“Your three clues to rule out blepharitis or contact lens on a small peripheral infiltrate: more pain than typically experienced, deep neovascularization and no clear zone between infiltrate and limbus,” Dr. Lighthizer offered.

While this patient had the marginal keratitis type of HSV, Dr. Lighthizer briefly reviewed all seven forms of the disease. Regarding treatment, he noted that Zirgan (ganciclovir 0.15%, Bausch + Lomb) is the sniper and Viroptic is the A-bomb. “Viroptic (trifluridine 1%, Pfizer) will take out the virus, and it may also take out the cornea,” he said. In a perfect world with no thoughts needed about costs and insurance coverage, Dr. Lighthizer would consider using both topical and oral antivirals. Regarding debridement, he would take the size of the ulcer into consideration. ■

**EYSUVIS (loteprednol etabonate ophthalmic suspension) 0.25%,
for topical ophthalmic use**

BRIEF SUMMARY OF FULL PRESCRIBING INFORMATION

INDICATIONS AND USAGE

EYSUVIS is a corticosteroid indicated for the short-term (up to two weeks) treatment of the signs and symptoms of dry eye disease.

CONTRAINDICATIONS

EYSUVIS, as with other ophthalmic corticosteroids, is contraindicated in most viral diseases of the cornea and conjunctiva including epithelial herpes simplex keratitis (dendritic keratitis), vaccinia, and varicella, and also in mycobacterial infection of the eye and fungal diseases of ocular structures.

WARNINGS AND PRECAUTIONS

Delayed Healing and Corneal Perforation—Topical corticosteroids have been known to delay healing and cause corneal and scleral thinning. Use of topical corticosteroids in the presence of thin corneal or scleral tissue may lead to perforation. The initial prescription and each renewal of the medication order should be made by a physician only after examination of the patient with the aid of magnification, such as slit lamp biomicroscopy, and, where appropriate, fluorescein staining.

Intraocular Pressure (IOP) Increase—Prolonged use of corticosteroids may result in glaucoma with damage to the optic nerve, as well as defects in visual acuity and fields of vision. Corticosteroids should be used with caution in the presence of glaucoma. Renewal of the medication order should be made by a physician only after examination of the patient and evaluation of the IOP.

Cataracts—Use of corticosteroids may result in posterior subcapsular cataract formation.

Bacterial Infections—Use of corticosteroids may suppress the host response and thus increase the hazard of secondary ocular infections. In acute purulent conditions of the eye, corticosteroids may mask infection or enhance existing infection.

Viral Infections—Use of corticosteroid medication in the treatment of patients with a history of herpes simplex requires great caution. Use of ocular corticosteroids may prolong the course and may exacerbate the severity of many viral infections of the eye (including herpes simplex).

Fungal Infections—Fungal infections of the cornea are particularly prone to develop coincidentally with long-term local corticosteroid application. Fungus invasion must be considered in any persistent corneal ulceration where a corticosteroid has been used or is in use. Fungal cultures should be taken when appropriate.

Risk of Contamination—Do not to allow the dropper tip to touch any surface, as this may contaminate the suspension.

Contact Lens Wear—The preservative in EYSUVIS may be absorbed by soft contact lenses. Contact lenses should be removed prior to instillation of EYSUVIS and may be reinserted 15 minutes following administration.

ADVERSE REACTIONS

Adverse reactions associated with ophthalmic corticosteroids include elevated intraocular pressure, which may be associated with infrequent optic nerve damage, visual acuity and field defects, posterior subcapsular cataract formation, delayed wound healing and secondary ocular infection from pathogens including herpes simplex, and perforation of the globe where there is thinning of the cornea or sclera.

Clinical Trials Experience—Because clinical trials are conducted under widely varying conditions, adverse reaction rates observed in the clinical trials of a drug cannot be directly compared to rates in the clinical trials of another drug and may not reflect the rates observed in practice.

The most common adverse reaction observed in clinical trials with EYSUVIS was instillation site pain, which was reported in 5% of patients.

USE IN SPECIFIC POPULATIONS

Pregnancy—Risk Summary: There are no adequate and well controlled studies with loteprednol etabonate in pregnant women. Loteprednol etabonate produced teratogenicity at clinically relevant doses in the rabbit and rat when administered orally during pregnancy. Loteprednol etabonate produced malformations when administered orally to pregnant rabbits at doses 1.4 times the recommended human ophthalmic dose (RHOD) and to pregnant rats at doses 34 times the RHOD. In pregnant rats receiving oral doses of loteprednol etabonate during the period equivalent to the last trimester of pregnancy through lactation in humans, survival of offspring was reduced at doses 3.4 times the RHOD. Maternal toxicity was observed in rats at doses 347 times the RHOD, and a maternal no observed adverse effect level (NOAEL) was established at 34 times the RHOD.

The background risk in the U.S. general population of major birth defects is 2 to 4%, and of miscarriage is 15 to 20%, of clinically recognized pregnancies.

Data—Animal Data: Embryofetal studies were conducted in pregnant rabbits administered loteprednol etabonate by oral gavage on gestation days 6 to 18, to target the period of organogenesis. Loteprednol etabonate produced fetal malformations at 0.1 mg/kg (1.4 times the recommended human ophthalmic dose (RHOD) based on body surface area, assuming 100% absorption). Spina bifida (including meningocele) was observed at 0.1 mg/kg, and exencephaly and craniofacial malformations were observed at 0.4 mg/kg (5.6 times the RHOD). At 3 mg/kg (41 times the RHOD), loteprednol etabonate was associated with increased incidences of abnormal left common carotid artery, limb flexures, umbilical hernia, scoliosis, and delayed ossification. Abortion and embryofetal lethality (resorption) occurred at 6 mg/kg (83 times the RHOD). A NOAEL for developmental toxicity was not established in this study. The NOAEL for maternal toxicity in rabbits was 3 mg/kg/day.

Embryofetal studies were conducted in pregnant rats administered loteprednol etabonate by oral gavage on gestation days 6 to 15, to target the period of organogenesis. Loteprednol etabonate produced fetal malformations, including absent innominate artery at 5 mg/kg (34 times the RHOD); and cleft palate, agnathia, cardiovascular defects, umbilical hernia, decreased fetal body weight and decreased skeletal ossification at 50 mg/kg (347 times the RHOD). Embryofetal lethality (resorption) was observed at 100 mg/kg (695 times the RHOD). The NOAEL for developmental toxicity in rats was 0.5 mg/kg (3.4 times the RHOD). Loteprednol etabonate was maternally toxic (reduced body weight gain) at 50 mg/kg/day. The NOAEL for maternal toxicity was 5 mg/kg.

A peri-/postnatal study was conducted in rats administered loteprednol etabonate by oral gavage from gestation day 15 (start of fetal period) to postnatal day 21 (the end of lactation period). At 0.5 mg/kg (3.4 times the clinical dose), reduced survival was observed in live-born offspring. Doses \geq 5 mg/kg (34 times the RHOD) caused umbilical hernia/incomplete gastrointestinal tract. Doses \geq 50 mg/kg (347 times the RHOD) produced maternal toxicity (reduced body weight gain, death), decreased number of live-born offspring, decreased birth weight, and delays in postnatal development. A developmental NOAEL was not established in this study. The NOAEL for maternal toxicity was 5 mg/kg.

Lactation—There are no data on the presence of loteprednol etabonate in human milk, the effects on the breastfed infant, or the effects on milk production. The developmental and health benefits of breastfeeding should be considered, along with the mother's clinical need for EYSUVIS and any potential adverse effects on the breastfed infant from EYSUVIS.

Pediatric Use—Safety and effectiveness in pediatric patients have not been established.

Geriatric Use—No overall differences in safety and effectiveness have been observed between elderly and younger adult patients.

NONCLINICAL TOXICOLOGY

Carcinogenesis, Mutagenesis, Impairment of Fertility—Long-term animal studies have not been conducted to evaluate the carcinogenic potential of loteprednol etabonate. Loteprednol etabonate was not genotoxic *in vitro* in the Ames test, the mouse lymphoma thymidine kinase (tk) assay, in a chromosome aberration test in human lymphocytes, or *in vivo* in the single dose mouse micronucleus assay. Treatment of male and female rats with 25 mg/kg/day of loteprednol etabonate (174 times the RHOD based on body surface area, assuming 100% absorption) prior to and during mating caused pre-implantation loss and decreased the number of live fetuses/live births. The NOAEL for fertility in rats was 5 mg/kg/day (34 times the RHOD).

**For a copy of the Full Prescribing Information, please visit
www.EYSUVIS.com.**

Manufactured for:
Kala Pharmaceuticals, Inc.
Watertown, MA 02472

Part # 2026R02

Marks designated by TM or [®] are owned by Kala Pharmaceuticals, Inc.
Patented. www.kalarx.com/patents

© 2020 Kala Pharmaceuticals, Inc. All rights reserved.

October 2020

Kala[®]

US-EYS-2000115

IN THE BATTLEGROUND OF DRY EYE...

When
Dry
Eye
Flares
strike,

fight
back
first
with
fast.



EYSUVIS is
an eye drop,
not a spray.

- EYSUVIS is **THE FIRST AND ONLY FDA APPROVED SHORT TERM (up to two weeks) RX TREATMENT** for the signs and symptoms of Dry Eye Disease
- EYSUVIS **RAPIDLY REDUCED*** Dry Eye signs and symptoms in the largest clinical development program in Dry Eye (N=2871)¹
- EYSUVIS **TARGETS OCULAR SURFACE INFLAMMATION**, an underlying pathology of Dry Eye
- EYSUVIS is formulated with AMPPLIFY® Drug Delivery Technology, designed to **ENHANCE OCULAR SURFACE TISSUE DISTRIBUTION AND PENETRATION**^{2,3}
- EYSUVIS had a **LOW INCIDENCE OF INTRAOCULAR PRESSURE ELEVATION (similar to vehicle) and was well-tolerated in clinical trials**⁴
–Please see Warning on Intraocular Pressure Increase below

*The safety and efficacy of EYSUVIS was assessed in 4 multicentered, randomized, double masked, placebo-controlled trials in 2871 patients with documented Dry Eye. Patients received either EYSUVIS or vehicle 4 times a day for at least 2 weeks. Patients using EYSUVIS showed significant reduction in the symptoms of Dry Eye (ocular discomfort) as early as Day 4 after starting treatment (versus vehicle). Symptoms continued to improve up to the end of the treatment period (Day 15). Patients using EYSUVIS also showed significant reduction in signs of Dry Eye (conjunctival hyperemia) at Day 15 versus vehicle.

INDICATION

EYSUVIS is a corticosteroid indicated for the short-term (up to two weeks) treatment of the signs and symptoms of dry eye disease.

IMPORTANT SAFETY INFORMATION

Contraindication:

EYSUVIS, as with other ophthalmic corticosteroids, is contraindicated in most viral diseases of the cornea and conjunctiva including epithelial herpes simplex keratitis (dendritic keratitis), vaccinia, and varicella, and also in mycobacterial infection of the eye and fungal diseases of ocular structures.

Warnings and Precautions:

Delayed Healing and Corneal Perforation: Topical corticosteroids have been known to delay healing and cause corneal and scleral thinning. Use of topical corticosteroids in the presence of thin corneal or scleral tissue may lead to perforation. The initial prescription and each renewal of the medication order should be made by a physician only after examination of the patient with the aid of magnification, such as slit lamp biomicroscopy, and, where appropriate, fluorescein staining.

Intraocular Pressure (IOP) Increase: Prolonged use of corticosteroids may result in glaucoma with damage to the optic nerve, as well as defects in visual acuity and fields of vision. Corticosteroids should be used with caution in the presence of glaucoma. Renewal of the medication order should be made by a physician only after examination of the patient and evaluation of the IOP.

Cataracts: Use of corticosteroids may result in posterior subcapsular cataract formation.

Bacterial Infections: Use of corticosteroids may suppress the host response and thus increase the hazard of secondary ocular infections. In acute purulent conditions, corticosteroids may mask infection or enhance existing infection.

EYSUVISTM
(loteprednol etabonate
ophthalmic suspension) 0.25%
THE FAST FLARE FIGHTER

**LEARN MORE ABOUT
EYSUVIS AT BOOTH 1113**

Viral Infections: Use of a corticosteroid medication in the treatment of patients with a history of herpes simplex requires great caution. Use of ocular corticosteroids may prolong the course and may exacerbate the severity of many viral infections of the eye (including herpes simplex).

Fungal Infections: Fungal infections of the cornea are particularly prone to develop coincidentally with long-term local corticosteroid application. Fungus invasion must be considered in any persistent corneal ulceration where a corticosteroid has been used or is in use.

Adverse Reactions:

The most common adverse drug reaction following the use of EYSUVIS for two weeks was instillation site pain, which was reported in 5% of patients.

Please see Brief Summary of Prescribing Information for EYSUVIS on the next page.

References: **1.** Holland E, Nichols K, Foulks G, et al. Safety and efficacy of KPI-121 ophthalmic suspension 0.25% for dry eye disease in four randomized controlled trials. Presented at: AAO 2020: November 13-15, 2020; virtual meeting. **2.** Schopf L, Enlow E, Popov A, et al. Ocular pharmacokinetics of a novel loteprednol etabonate 0.4% ophthalmic formulation. *Ophthalmol Ther.* 2014;3(1-2):63-72. **3.** Popov A. Mucus-penetrating particles and the role of ocular mucus as a barrier to micro- and nanosuspensions. *J Ocul Pharmacol Ther.* 2020;36(6):366-375. **4.** Korenfeld M, Nichols KK, Goldberg D, et al. Safety of KPI-121 ophthalmic suspension 0.25% in patients with dry eye disease: a pooled analysis of 4 multicenter, randomized, vehicle-controlled studies. *Cornea.* 2020. In press.

kala
PHARMACEUTICALS

US-EYS-2100081

www.EYSUVIS.com